

Chest Wall Resection Prosthesis

Daniel Haberek, *Biomedical Engineering, University of Rhode Island*
BME 281 First Presentation, September 23, 2016 <dan.haberek@gmail.com>

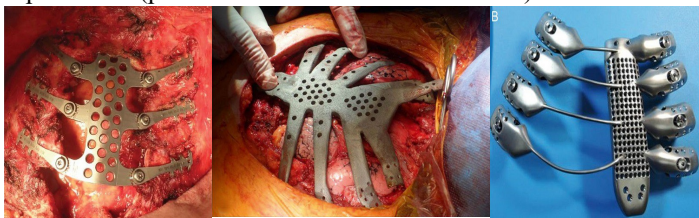
Abstract— Chest wall resections are a surgery performed most commonly in patients with post-operative chest-structure collapse due to removal of a tumor, infection, or other trauma. The resections work to restore structure and allow patient lung function to continue as normal. Modern approaches to the surgery hope to reduce post-operative complications.

I. INTRODUCTION

THE process of reconstructing part of the chest wall after loss of structure begins its history in the 18th century [3]. Since then, many medical advances have been realized, and the surgery has been improved through anesthesia, antibiotics, and, lately, titanium plates and 3D printing of prosthesis. Chest wall resection is a high risk surgery, in terms of modern medicine (one study found death in 3.8% of post-operative patients, and complications in 59% of other patients), but new advances suggest that the surgery is becoming safer [5].

II. METHODS

Modern chest wall resection surgeries have moved from the traditional bone graft and soft tissue method to 3D printed titanium plating with anchors and mesh or soft tissue cover. The aim of the prosthesis is to prevent structural collapse and infection within the thoracic cavity. Within three modern case studies, three different methods have been approached. The first case details a woman who experienced breast cancer metastasis in her sternum. In this case, a custom titanium neosternum without mesh for positioning was used [2]. The second case also focuses on a woman with breast cancer, but with more severe tumors; a titanium prosthetic of the sternum and seven ribs with soft tissue grafting was designed in this case[4]. The final case details a man who suffered from metastatic bone tissue in his chest; a 3D printed titanium sternum with titanium rods for pseudo-rib structures was used [1]. Pictures displaying the structures described above are shown below and give better representation of the differences in prosthesis (pictures shown are in order as cited).



Within all three cases, a pre-operative CT scan was conducted in order to get custom measurement for the prosthetic. The prosthesis were then designed in 3D software.

III. RESULTS

Between the three cases, installation of the prosthesis and

overall surgery went smoothly and without event. In the first case, which dates in August 2013, the patient experienced no post-operative stress within the three months following the procedure, but developed additional bone metastases. While this does not reflect negatively on the titanium prosthetic, it does raise a question of post-operative treatment of additional metastases. The second case, dating September 2013, showed more promising results. The patient was released after seven days of post-operative care and after six months of post-operative life, showed no complications at the site of the prosthetic. In the third case, dating June 2015, the 3D printed titanium prosthetic integrated into the patient's system seamlessly without infection or other complication.

IV. DISCUSSION

The three aforementioned cases show great promise in regard to the future of chest wall resection surgeries. In past cases, infection, pneumonia, and rejection of the prosthetic were of great concern when considering the surgery. With modern developments in the field of thoracic surgery, the likelihood of treating patients suffering from metastases successfully has greatly increased.

Though the surgery is effective and promising, it is still unclear as to the practicality of the operation. In the case of the 3D printed sternum and pseudo-ribs, the prosthetic took a month to design and print before being installed. Due to the nature and urgency of resection surgeries, this is an almost overwhelming hurdle to climb over. There is also a lack of post-operative data in regard to the new prosthesis, and the long-term consequences and side effects have yet to be seen.

Hopefully within the next decade new developments and further studies can be conducted that makes this new, safe option more accessible to the general public.

REFERENCES

- [1] Aranda J, Jiménez M., Rodriguez M, Varela G. *Tridimensional titanium-printed custom-made prosthesis for sternocostal reconstruction. Eur J Cardiothorac Surg.* 2015.
- [2] Demondion P, Mercier O, Kolb F, Fadel E. *Sternal replacement with a custom-made titanium plate after resection of a solitary breast cancer metastasis. Interact CardioVasc Thorac Surg* 2014;18:145–7.
- [3] Mansour K, Thourani V, Losken A, Reeves J, Miller Jr J, Carlson G, Jones G. *Chest wall resections and reconstruction: a 25-year experience.* 2002.
- [4] Turna A, Kavakli K, Sapmaz E, Arslan H, Caylak H, Gokce HS, et al. *Reconstruction with a patient-specific titanium implant after a wide anterior chest wall resection. Interact CardioVasc Thorac Surg* 2014;18:234–6.
- [5] Wevant M, Bains M, Venkatraman E, Downey R, Park B, Flores R, Rizk N, Rusch V. *Results of Chest Wall Resection and Reconstruction With and Without Rigid Prosthesis.* 2005.